

Fragile X-Associated Tremor/Ataxia Syndrome: Clinical Features, Genetics, and Testing Guidelines

Elizabeth Berry-Kravis, MD, PhD,^{1,2,3*} Liane Abrams, MS, CGC,⁴ Sarah M. Coffey, MPH,^{5,6} Deborah A. Hall, MD,⁷ Claudia Greco, MD,⁸ Louise W. Gane, MS,⁶ Jim Grigsby, PhD,⁹ James A. Bourgeois, OD, MD,¹⁰ Brenda Finucane, MS, CGC,¹¹ Sebastien Jacquemont, MD,¹² James A. Brunberg, MD,¹³ Lin Zhang, MD, PhD,¹⁴ Janet Lin, MD,¹⁵ Flora Tassone, PhD,¹⁶ Paul J. Hagerman, MD, PhD,¹⁶ Randi J. Hagerman, MD,^{5,6} and Maureen A. Leehey, MD¹⁷

¹Department of Pediatrics, Rush University Medical Center, Chicago, Illinois

²Department of Neurological Sciences, Rush University Medical Center, Chicago, Illinois

³Department of Biochemistry, Rush University Medical Center, Chicago, Illinois

⁴National Fragile X Foundation, San Francisco, California

⁵Department of Pediatrics, University of California at Davis Medical Center, Sacramento, California

⁶MIND Institute, University of California at Davis Medical Center, Sacramento, California

⁷Department of Neurology, University of Colorado Health Sciences Center, Denver, Colorado

⁸Department of Pathology, University of California, Davis School of Medicine, Davis, California

⁹Department of Medicine, University of Colorado Health Sciences Center, Denver, Colorado

¹⁰Department of Psychiatry and Behavioral Sciences, University of California, Davis Medical Center, Sacramento, California

¹¹Genetic Services, Elwyn Inc, Elwyn, Pennsylvania

¹²Service de génétique Médicale, CHUV, Lausanne, Switzerland

¹³Department of Radiology, University of California at Davis Medical Center, Sacramento, California

¹⁴Department of Neurology, University of California at Davis School of Medicine, Sacramento, California

¹⁵Neurology Medical Group-Diablo, Walnut Creek, California

¹⁶Department of Biochemistry and Molecular Medicine, University of California, Davis School of Medicine, Davis, California

¹⁷Department of Neurology, University of Colorado at Denver and Health Sciences Center, Denver, Colorado

Abstract: Fragile X-associated tremor/ataxia syndrome (FXTAS) is a neurodegenerative disorder with core features of action tremor and cerebellar gait ataxia. Frequent associated findings include parkinsonism, executive function deficits and dementia, neuropathy, and dysautonomia. Magnetic Resonance Imaging studies in FXTAS demonstrate increased T2 signal intensity in the middle cerebellar peduncles (MCP sign) in the majority of patients. Similar signal alterations are seen in deep and subependymal cerebral white matter, as is general cortical and subcortical atrophy. The major neuropathological feature of FXTAS is the presence of intranuclear, neuronal, and astrocytic, inclusions in broad distribution throughout the brain and brainstem. FXTAS is caused by moderate expansions (55–200 repeats; premutation range) of a CGG trinucleotide in the fragile X mental retardation 1 (*FMR1*) gene, the same gene

which causes fragile X syndrome when in the full mutation range (200 or greater CGG repeats). The pathogenic mechanism is related to overexpression and toxicity of the *FMR1* mRNA per se. Although only recently discovered, and hence currently under-diagnosed, FXTAS is likely to be one of the most common single-gene disorders leading to neurodegeneration in males. In this report, we review information available on the clinical, radiological, and pathological features, and prevalence and management of FXTAS. We also provide guidelines for the practitioner to assist with identifying appropriate patients for DNA testing for FXTAS, as well as recommendations for genetic counseling once a diagnosis of FXTAS is made. © 2007 Movement Disorder Society

Key words: fragile X-associated tremor/ataxia syndrome; tremor; ataxia; FMR1; fragile X syndrome

This article is part of the journal's CME program. The CME form can be found on page 2140 and is available online at <http://www.movementdisorders.org/education/activities.html>

This article includes supplementary video clips, available online at <http://www.interscience.wiley.com/jpages/0885-3185/suppmat>.

*Correspondence to: Dr. Elizabeth Berry-Kravis, Rush University Medical Center, 1725 West Harrison, Suite 718, Chicago, IL 60612. E-mail: Elizabeth_m_berry-kravis@rush.edu

Received 10 November 2006; Revised 21 February 2007; Accepted 3 March 2007

Published online 6 July 2007 in Wiley InterScience (www.interscience.wiley.com). DOI: 10.1002/mds.21493

Fragile X-associated tremor/ataxia syndrome (FXTAS) is a late onset (>50 years) neurodegenerative disorder, occurring in carriers of a premutation CGG-repeat expansion in the fragile X mental retardation 1 (*FMRI*) gene.¹ The disorder consists of intention tremor, ataxia, parkinsonism, cognitive decline, neuropathy, and psychiatric features along with Magnetic Resonance Imaging (MRI) findings of increased signal intensity in the middle cerebellar peduncles (MCP sign) on T2-weighted images or FLAIR sequences in many affected persons.²⁻⁴ The penetrance of FXTAS in male carriers over 50 years is ~40%, with an age-related penetrance of 17%, 38%, 47% and 75% for male carriers aged 50 to 59, 60 to 69, 70 to 79, and ≥80 years, respectively.⁵ Penetrance in females is much lower and female carriers only infrequently develop FXTAS. It is estimated that 1 of 259 females⁶ and 1 of 813 males⁷ in the general population are carriers of an *FMRI* premutation, suggesting that for males, FXTAS may be one of the most common late-onset, progressive neurological diseases associated with a single gene mutation, similar in prevalence to other neurodegenerative diseases such as multiple system atrophy and amyotrophic lateral sclerosis.

The *FMRI* gene, located on the X chromosome, has a trinucleotide (CGG) repeat in the 5' untranslated region of the gene.⁸ The normal repeat length is 5-44 CGG triplets; "gray zone" alleles are defined as 45-54, premutation alleles as 55-200, and full mutations as above 200 CGG repeats.⁹ Repeat lengths in the gray zone may occasionally be unstable, or expand, when passing from one generation to the next,¹⁰ but are not known to cause disease.

Full mutation alleles result in hypermethylation and silencing of the *FMRI* gene¹¹ and consequent deficiency or absence of *FMRI* protein (FMRP).¹² FMRP is an RNA-binding protein thought to regulate translation at the dendrite in response to glutamatergic neural activation,¹³ thereby modulating synaptic plasticity, and dendritic morphology.¹⁴ Absence or deficiency of FMRP results in fragile X syndrome (FXS).^{12,15} With a population prevalence of about 1 of 3,600,¹⁶ FXS is the most common inherited form of mental retardation and is characterized by cognitive, speech and behavioral disabilities, hypotonia, and motor coordination problems and autistic features. Physical signs including a long face and prominent ears are present in many individuals with FXS,¹⁷ and seizures occur in about 15%, most commonly in young children.¹⁸ Because of the presence of a presumably normal *FMRI* allele on the second X chromosome, females with a full mutation are more mildly affected than males, but can have a range of associated features, both physical and developmental.

Some premutation carriers have been found to have subtle evidence of features that overlap those seen in FXS.¹⁹ Some female premutation carriers have emotional problems including anxiety, obsessive thinking, and/or depression.²⁰⁻²² Male carriers show increased obsessive-compulsive symptoms relative to a control group, independent of presence, and severity of motor signs of FXTAS.²³ Cornish et al.²⁴ found social deficits and obsessive thinking in adult male carriers. A recent study of boys with the premutation who presented with developmental delay showed higher rates of autistic behavior compared to their brothers without the premutation.²⁵ A small subgroup of carriers have cognitive disorders or features of FXS, predominantly those with a larger premutation and evidence of a deficit in FMRP.²⁶⁻²⁸

Previously there was no recognized clinical phenotype specific to premutation carriers. In recent years, however, two such phenotypes have emerged. The first was premature ovarian failure (POF), defined as the cessation of menses before age 40, which occurs in ~20% of female carriers.²⁹ Even in female carriers who do not have POF, FSH is elevated, suggestive of ovarian dysfunction.³⁰ The second phenotype is FXTAS, the focus of this review, which occurs in a proportion of carriers, and in men more often than women.⁵

CLINICAL PHENOTYPE OF FXTAS: NEUROLOGICAL, PSYCHOLOGICAL, AND PSYCHIATRIC

The mean (\pm SD) age of onset of FXTAS is 60.2 (\pm 7.2), and larger CGG repeat number in the *FMRI* premutation correlates with earlier age of onset of tremor and ataxia.³¹ The major motor features are intention or postural (action) tremor, cerebellar gait and limb ataxia, and parkinsonism.^{2,32-36} These features are demonstrated on the accompanying video clips (see video legend). Tremor on the Clinical Rating Scale for Tremor (CRST) and limb ataxia on the International Cerebellar Ataxia Rating Scale (ICARS) were distinct clinical features identified in adult male premutation carriers as compared to appropriately defined age-matched mixed gender control group.³³ Tremor on the CRST, and limb ataxia and gait/stance ataxia on the ICARS were abnormal in additional groups of male carriers relative to age-matched male controls.^{5,37} Age of onset of both tremor and ataxia have been found to correlate with CGG repeat length.³⁸ As evidenced by the statistically significant differences in all subdomains of the CRST,³³ the tremor of this phenotype is multidimensional, involving rest, postural, and kinetic elements. Postural and kinetic tremors are typically more obvious initially and rest tremor some-

times appears as the condition progresses. The gait is typically slow and lurching, and patients have difficulty with tandem stance and gait, consistent with cerebellar ataxia. Parkinsonian signs, primarily rigidity,³³ are usually less obvious. This suggests that the phenotype in FXTAS premutation carriers is not a typical presentation of Parkinson disease, but instead an overlapping tremor-predominant syndrome with cerebellar ataxia and mild parkinsonism. Despite high inter-individual variation in the phenotype, even within families,³⁹ the mixture of cerebellar gait ataxia, postural/intention tremor, and parkinsonism in older men is characteristic of FXTAS but overlaps the spectrum of clinical features observed in some of the inherited cerebellar ataxias and multiple system atrophy—cerebellar subtype (MSA-C).

In addition to tremor and ataxia, anecdotal reports suggest that neuropathic and autonomic dysfunction occurs in FXTAS.^{1,5,34,40} Signs of peripheral neuropathy, including decreased reflexes and impaired vibration sense in the distal lower extremities, are present in many affected persons, and are found more frequently in male premutation carriers than in matched controls.⁴¹ Severity of neuropathic signs correlates with CGG repeat length and with severity of ataxia in both male and female premutation carriers.⁴¹ Some individuals also have evidence of substantial autonomic dysfunction, including orthostatic hypotension,⁴⁰ impotence, and, eventually, progressive loss of bowel and bladder control.

Cognitive deficits are frequent in FXTAS. Heretofore, the most characteristic type of dementia seen in FXTAS is a dysexecutive syndrome; the pattern of deficits is similar to that observed in several of the spinocerebellar ataxias, the frontal variant of frontotemporal dementia, and multiple system atrophy.⁴²⁻⁴⁴ The initial signs of cognitive impairment in FXTAS appear to be relatively subtle deficits of the executive cognitive functions (ECF) and working memory.^{45,46} Because these initial ECF deficits are not obvious, they may be overlooked until they begin to affect behavior, at which time they may be viewed as indicative of personality change. There appears to be little impairment of primary declarative memory, especially episodic recall, until later in the disorder. Constructional praxis, visuospatial functioning, and language are typically intact.

Although there is considerable variability in the progression and nature of cognitive impairment, individuals with FXTAS typically score lower than healthy persons of the same age and education on a number of cognitive measures, including WAIS-III Performance (nonverbal) IQ, as well as measures of ECF and information processing speed. Verbal reasoning, as measured by the WAIS-III verbal IQ, is relatively unaffected in FXTAS, with the

exception of those subtests dependent on working memory (Arithmetic and Digit Span).

One of the most striking executive cognitive deficits as FXTAS advances is impairment in the initiation of purposeful, goal-directed activity, and in the inhibition of inappropriate or irrelevant behavior. As insight becomes increasingly affected, patients become oblivious to rather remarkable behavioral and cognitive slips and errors. Measures such as the Neuropsychiatric inventory, which quantitate behavioral consequences of dementia, may be more abnormal in FXTAS than overall cognitive screening instruments such as the Folstein mini mental state examination (MMSE). This latter test may be paradoxically relatively well-preserved early in the dementia that occurs in FXTAS, as the MMSE does not assess executive cognitive deficits directly.⁴

The speed of information processing is slowed and its capacity is decreased.⁴⁷ Deficits in semantic memory—especially retrieval—are common, probably secondary to the dysexecutive syndrome. Language and verbal reasoning are relatively spared, at least until late in the disorder. It is as yet unknown when cognitive impairment begins in relation to the neurological signs of FXTAS or whether progressions of motor and cognitive signs correspond. However, given findings of subtle executive disorders among carriers of premutation alleles ascertained without regard to the presence or absence of motor signs of FXTAS,^{48,49} cognitive issues may be present early on.

FXTAS can be associated with a combination of psychiatric features that may appear either sequentially or in combination.^{4,50} As the motor symptoms of FXTAS emerge and progress, the psychiatric symptoms change over time as well. Because all of the psychiatric symptom groups seen in FXTAS are commonly seen in premutation carriers without neurological illness^{23,24} and are often associated with neurological illness unrelated to FXTAS (such as Parkinson disease), the relationship between FXTAS and psychiatric illness remains correlative, rather than causal. The psychiatric symptoms seen in FXTAS often follow the establishment of motor symptoms that are quite disabling. Thus, it is possible that some of the psychiatric symptoms in FXTAS may be partially residual to the “stress” and disruption of living with a disabling illness and the psychosocial loss this represents.

The neuropsychiatric comorbidity of FXTAS appears to consist of anxiety disorders, mood disorders (primarily of the depressed type), and dementia.^{4,51} In some cases the anxiety and/or mood disorder may serve as a psychiatric prodrome of the later motor involvement.²³ The anxiety disorder is similar to generalized anxiety disorder.

der, wherein patients chronically experience an increased “tonic” level of anxiety, as opposed to episodes of acute and time-limited bouts of extreme anxiety, as seen in specific phobia or panic disorder.

The mood disorder of FXTAS reported frequently in studies to date is of the depressed type, with variable neurovegetative signs.^{4,51} As with depressive disorders in the context of a general medical or neurological illness, these depressed episodes do not necessarily meet diagnostic criteria for major depressive disorder. Dementia presents concurrently with anxiety or mood disorders in some cases.⁵⁰

On the basis of clinical information available to date, diagnostic criteria for FXTAS have been proposed.³⁴ These criteria, outlined in Table 1, have been useful in clinical studies. In routine medical practice, however, the diagnosis can be made by finding of the *FMRI* premutation in a person with a late onset neurological disorder (however mild) consistent with previously published cases. Presence of the MCP sign on MRI is useful in confirming the diagnosis, but not necessary, since to date the frequency of this radiographic sign among affected carriers is ~60%.³⁴

INVOLVEMENT IN FEMALES

FXTAS affects predominantly male premutation carriers as evidenced by the lack of significant differences between groups of female carriers and controls when rated with the CRST, ICARS, or UPDRS,^{33,34} although individual female carriers do occasionally have clinical and neuropathological features of FXTAS.^{39,51-54} Penetrance estimates for females are not yet available and are the subject of ongoing study, although will likely be less than 10% overall for females over age 50 (Berry-Kravis E, Hagerman R, unpublished data). The neurological symptoms are almost always much milder in females than males, presumably due to a variable degree of protection provided by the expression of *FMRI* from the normal allele on the active X chromosome in a percentage of cells. Indeed, females with FXTAS symptoms tend to have skewed X-inactivation, with a greater fraction of cells expressing an active premutation.^{51,54}

RADIOLOGICAL FEATURES OF FXTAS

MR imaging findings associated with FXTAS (Figs. 1 and 2) include diffuse cerebral, brainstem and cerebellar volume loss, and increased T2 signal intensity in white matter of the MCP, and in underlying cerebellar white matter lateral to the dentate nuclei (Fig. 1).³ The MCP sign is not specific to FXTAS; and not all patients with FXTAS demonstrate this finding.^{55,56} FXTAS-associated MRI findings also include patchy or confluent areas of

TABLE 1. Proposed diagnostic criteria and categories for FXTAS^a

Criteria	
Molecular	55 to 200 CGG repeats
Clinical	
Major	Intention tremor Cerebellar gait ataxia
Minor	Parkinsonism Moderate to severe working memory deficit Executive function deficit
Radiological	
Major	MRI white matter lesions involving middle cerebellar peduncles
Minor	MRI lesions involving cerebral white matter Moderate to severe generalized brain atrophy
Diagnostic categories	
Definite	One major clinical, and one major radiological, or presence of FXTAS inclusions
Probable	Two major clinical, or one minor clinical, and one major radiological
Possible	One major clinical, and one minor radiological

^aAdapted from Jacquemont et al.²

increased signal intensity on T2 weighted or FLAIR images in periventricular and deep white matter of the cerebral hemispheres and corpus callosum (Fig. 2). These cerebral alterations are more prominent than in age-matched controls.^{3,57} Volumetric studies, performed in aging male carriers with and without FXTAS, also reveal significant volume loss involving the cerebellum, cerebral cortex, amygdalo-hippocampal complex, thalamus, and brainstem.^{58,59} Cerebellar volume loss, increased ventricular volume, and whole brain white matter hyperintensity correlate with CGG repeat length in premutation carriers.⁵⁷ The above-described constellation of MRI findings in an aging male should lead to consideration of FXTAS, particularly if the MCP sign is present.

PATHOLOGICAL FEATURES OF FXTAS

The pathological diagnosis of FXTAS is currently made only at autopsy, which has been reported for 1 female and 11 male premutation carriers to date.^{52,60-62} The pathological hallmark of FXTAS is the presence of intranuclear inclusions in neurons and astrocytes throughout the brain. The inclusions are ubiquitin positive on immunostaining of paraffin-embedded sections. Electron microscopic evaluation shows nonmembrane bound collections of granulofilamentous material. Further immunohistochemical and mass spectrometric analyses of purified brain inclusions show them to be associated with more than 20 proteins and *FMRI* mRNA.⁶³⁻⁶⁵

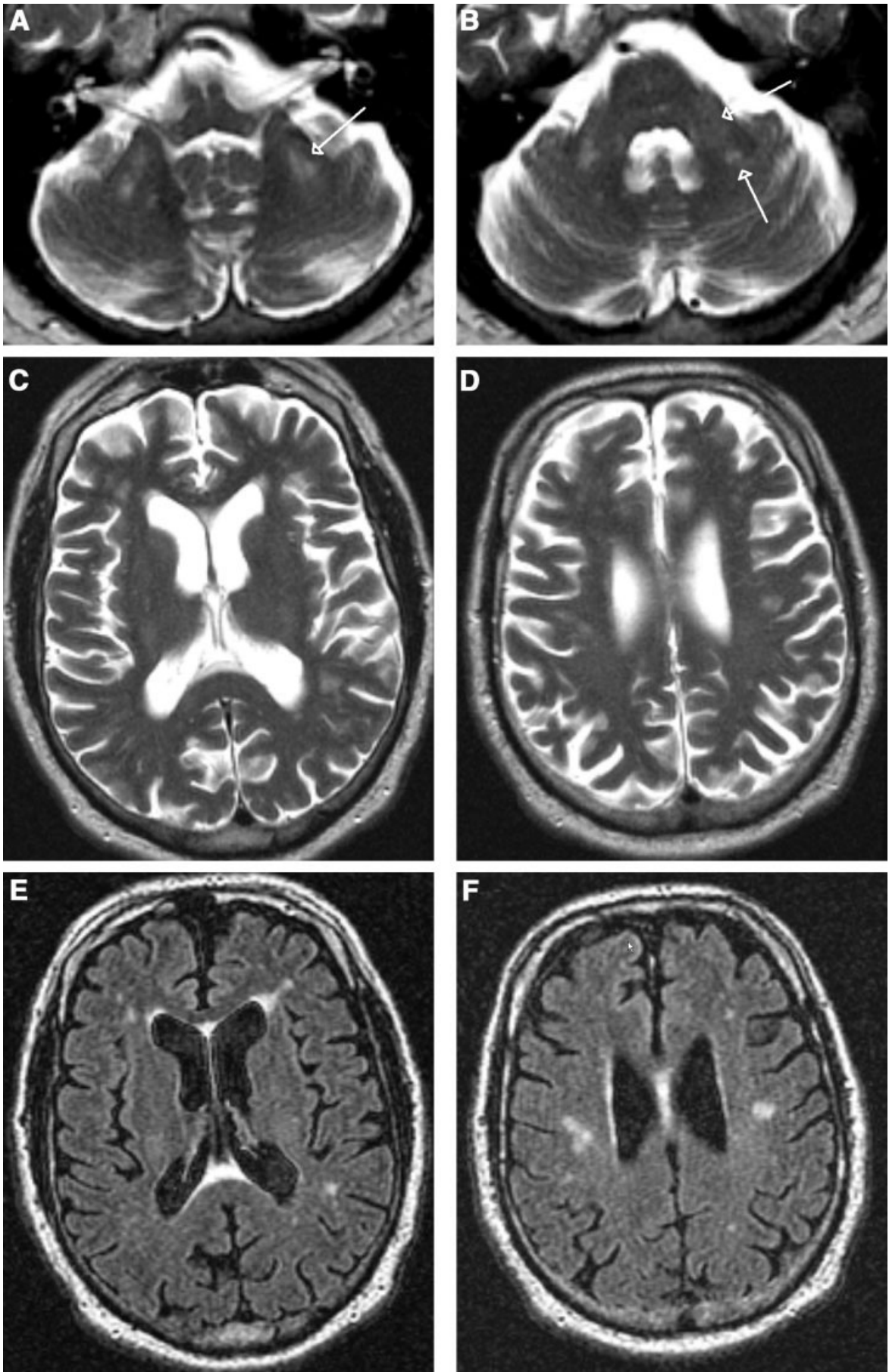


FIGURE 1.

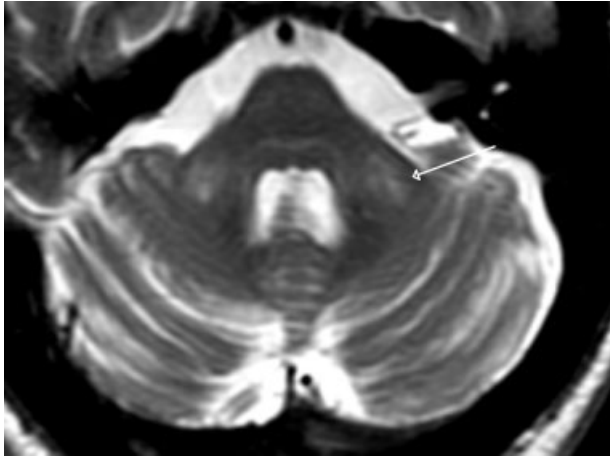


FIG. 2. Fifty-nine-year-old male with FXTAS. T2 weighted MR image demonstrates moderate bilateral increase in MCP signal intensity and mild thinning of the oblique transverse diameters of both MCPs. There is mild cerebellar cortical volume loss.

These findings support the RNA gain-of-function mechanism that has been proposed for FXTAS.⁶⁶ This mechanism was based on the finding of elevated *FMR1* mRNA levels in cells from premutation carriers, corresponding to and presumably compensating for a translational deficit for FMRP produced from premutation alleles, particularly at larger CGG repeat sizes.⁶⁷ Accumulated *FMR1* mRNA containing the CGG repeat is then thought to exert a neurotoxic effect by sequestering and perturbing function of nuclear proteins.^{60,61,66} This mechanism is also consistent with the finding of nuclear inclusions in mice expressing an *FMR1* gene with a premutation expansion allele (~100 CGG repeats),⁶⁸ and with studies showing neurodegeneration in *Drosophila* expressing an expanded CGG repeat.⁶⁹ As predicted by the *FMR1* mRNA toxicity mechanism for FXTAS, individuals with the *FMR1* full mutation and FXS do not develop FXTAS because the *FMR1* gene silencing in FXS results in absent or reduced *FMR1* mRNA and FMRP. Figure 3 illustrates the relationships between *FMR1* CGG repeat length, type of mutation (full or premutation), *FMR1* mRNA levels, FMRP levels, and clinical phenotype.

The nuclear inclusions in FXTAS are most numerous in the hippocampal formation, and are only rarely seen in Purkinje cells. The number of CGG repeats is highly correlated with the fraction of inclusion-bearing neural

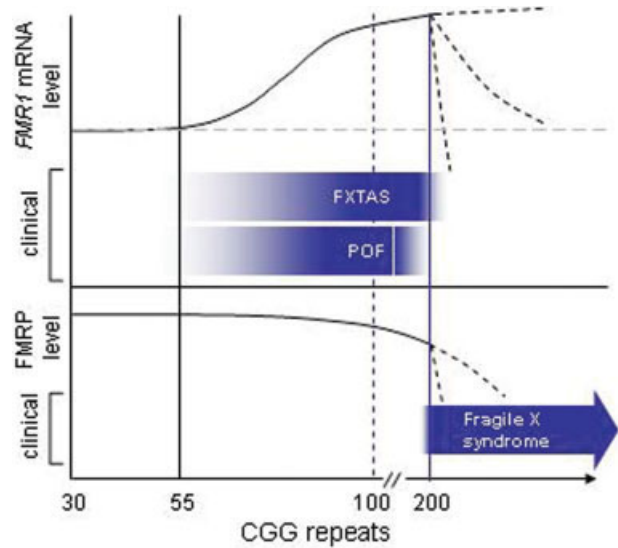


FIG. 3. Graphs of the relative levels of *FMR1* mRNA and protein (FMRP) as a function of the number of CGG repeats, and the associated clinical phenotypes. FXTAS and POF are largely confined to the premutation range, and are thought to occur through an RNA toxic gain-of-function due to excess *FMR1* mRNA; however, occasional patients with full mutation alleles continue to express mRNA and are at risk of developing FXTAS. By contrast, fragile X syndrome is caused by reduced/absent FMRP, due to silencing of the *FMR1* gene in the full mutation range, and is generally confined to the full mutation range. Features of the fragile X syndrome spectrum may occur in the upper premutation range due to reduced protein production. Dashed lines for mRNA levels in the full mutation range reflect variations in degree of silencing; dashed lines for FMRP levels represent reductions due to both lowered mRNA levels and intrinsic reductions in translational efficiency. [Color figure can be viewed in the online issue, which is available at www.interscience.wiley.com.]

cells in cases studied thus far.⁶¹ The inclusions have been identified in the hypoglossal cranial nerve nucleus. Inclusions have not been identified in motor neurons of the spinal cord, although they are present in spinal autonomic neurons and astrocytic nuclei of the spinal cord.⁶¹ Patches of subcortical white matter pallor and spongiosis with axonal spheroids are present to varying degrees in white matter, accompanied by loss of axons and myelin. These changes correspond to areas of increased T2-weighted signal intensity seen on T2-weighted MR imaging of the same individuals. Despite the obvious abnormal appearance of the MCP sign on MRI images, only a mild degree of spongiosis, with rare swollen axons, is found in the MCP at autopsy. Deep cerebellar white matter in the region of the dentate nucleus shows

FIG. 1. Fifty-year-old male with FXTAS. (A–D): T2 weighted MR images. (E,F): Inversion recovery MR images. A and B: There is increased signal intensity in the middle cerebellar peduncles that is both mild (anterior arrow in B) and moderate (posterior arrow in B) in severity, and extends into the deep white matter of the cerebellum adjacent to the dentate nuclei (arrow in A). (C–F): There is moderate cortical volume loss and mild increase in volume of the lateral ventricles. There are nonspecific regions of increased signal intensity in frontal and parietal white matter, most conspicuous on matching inversion recovery images (E,F). The cerebral white matter changes are mild in severity for subjects with FXTAS.

variable degrees of spongiosis and axonal and myelin loss. The more severe cases also show scattered, markedly enlarged astrocytes in white matter presumably containing phagocytosed cytoplasmic material.

The current diagnostic criteria for FXTAS outlined in Table 1, originally published in Jacquemont et al.,³⁴ have been modified to include the presence of inclusions when brain tissue is available.⁶⁶ Inclusions have also been recently identified in the anterior and posterior pituitary^{62,70} and in the Leydig cells and myotubular cells of the testicles in two males with FXTAS.⁷⁰

FXTAS SCREENING IN MOVEMENT DISORDERS COHORTS

The discovery of FXTAS prompted exploration of the contribution of the *FMRI* premutation to disorders with similar clinical features. The results of several cross-sectional studies screening for *FMRI* repeat expansions in movement disorder populations are shown in Table 2.^{54,71-81} The prevalence of premutation alleles in men with ataxia in a meta-analysis of studies published before 2006^{54,71-73,75,77,79,80,83} was 1.5% (16/1,049), thirteen times more than expected based on the prevalence of the premutation in the general population. A more recent study⁸⁴ suggested a similar frequency (3/142, 2.1%) of premutation alleles in men screened in an ataxia clinic. Screening of patients with the cerebellar subtype of mul-

iple system atrophy^{73,74,79,81,82,85} showed 2.4% (4/167) had premutations, while screening of other movement disorders populations was unrewarding.^{74,76,78-80,86,87} In most cases when the *FMRI* premutation was found, the clinical description of the premutation carriers suggested that FXTAS was the patient's actual diagnosis, rather than a statistical association. Thus, in the vast majority of the cases presented in Table 2, the identification of a premutation allowed confirmation of a diagnosis of FXTAS.

As has been pointed out previously,⁸⁸ the results of these screening studies yielded smaller prevalence rates than expected. These studies likely underestimate the true contribution of the *FMRI* premutation in movement disorders for a number of reasons. Several of the studies included patients under the age of 55. Also, the percentages derived are based on low numbers of premutation carriers identified and the confidence intervals include zero, suggesting that larger populations would need to be screened to generate accurate prevalence rates. Further, the movement disorder cohorts screened were recruited based on specific clinical criteria, which in many cases would likely exclude patients with FXTAS. For example, the screened essential tremor patients were required to have a first-degree relative with essential tremor, and patients with PD and MSA were required to have no atypical signs, such as dementia. Lack of dementia may exclude up to 50% of patients with FXTAS.

Another reason that these studies likely underestimate the importance of the contribution of the *FMRI* premutation to movement disorders is that the screened ataxia population had been ascertained on the basis of being referred for genetic testing for ataxia. FXTAS patients are rarely referred for genetic testing for ataxia, and only ~17%⁸⁹ had been given a diagnosis of ataxia before they were found to have FXTAS. The low frequency of ataxia diagnoses in patients with FXTAS seems to be related to the multiplicity of neurological problems and neuroimaging findings seen in these patients, such that they are not typically seen as having a primary diagnosis of ataxia. Rather the overall clinical picture for many patients with FXTAS is hard to classify as a defined neurological condition, and thus patients may receive a broad range of diagnoses such as stroke and multiple sclerosis.⁸⁹ Further, unlike most inherited ataxias, individuals with FXTAS from the same family may present with a very different constellation of clinical symptoms and neuroimaging findings.³⁹

Interestingly, only a small proportion (4%) of FXTAS patients with movement disorders were referred to movement disorder specialists⁸⁹; thus, the estimates for premutation alleles in those populations probably underes-

TABLE 2. Frequency of *FMRI* premutation alleles in populations with movement disorders^a

Clinical diagnosis	Premutation allele/sample size	
	Men	Women
PD ^b	1/903	1/225
Atypical PD	0/40	0/11
Essential tremor	0/270	0/78
MSA ^c	2/366	3/297
MSA-P ^d		1/341
MSA-C ^d	4/280 (4/167) ^e	
Cerebellar ataxia	16/1049 ^f	1/549
Total	18/2628	5/1160

^aTable is adapted from Jacquemont et al.⁸¹

^bPD, Parkinson's disease. From Tan et al.⁷⁸ only the late-onset PD group is included because gender was not reported for the remainder of the subjects.

^cMSA, Multiple system atrophy. Includes possible, probable, and definite MSA as defined in Gilman et al.⁸²

^dMSA-P, parkinsonian subtype of MSA; MSA-C: cerebellar subtype of MSA. The subtype and gender was not provided for all patients.

^eParentheses indicate the subgroup of probable MSA, meaning they have definite signs of MSA and are diagnosed while alive. A significantly higher (4/167; 2.4%) number of persons with probable MSA-C had *FMRI* premutations than present in the normal population ($P < 0.01$).

^fA significantly higher (16/1049; 1.5%) number of males with cerebellar ataxia had *FMRI* premutations than present in the normal population ($P < 0.001$).

timate the numbers of individuals presenting with such features as parkinsonism, gait ataxia, or other neurological signs. In addition, premutation rates vary with ethnicity, with some populations, such as ethnic Chinese, having lower rates than others.⁹⁰ Although these studies yield frequency estimates for *FMRI* repeat expansions in movement disorders, prospective studies are needed.

TESTING FOR FXTAS

Diagnosis of both FXTAS and FXS is accomplished through DNA analysis designed to evaluate the size of the CGG repeat sequence in *FMRI*. The DNA test performed is the same for identification of either FXS or FXTAS, and may be termed fragile X DNA test, *FMRI* DNA test, or FXTAS DNA test, depending on the laboratory. The fragile X DNA test is readily available at University and commercial laboratories in the USA and through health services laboratories in many countries. On the basis of current literature, reasonable guidelines for testing for FXS and FXTAS are presented in Table 3 and Table 4, respectively.

NATURAL HISTORY OF FXTAS

Since FXTAS has only recently been described, information about the natural history of the disorder has primarily been inferred from the multiple case histories that have been published.^{1,2,35,39,61,85} Definition of the natural history of FXTAS is difficult because the initial symptoms may be subtle, e.g., ECF dysfunction, and difficult to recognize. Recently, a family-based, retrospective, longitudinal study³⁶ analyzed the progression of motor deficits related to tremor and ataxia and the length of survival after onset in 55 male premutation carriers. Onset of disease was defined as the first report of tremor or ataxia. Tremor usually occurred first, with median onset at ~60 years. From occurrence of the initial motor sign, median delay of onset of ataxia was

TABLE 3. Testing guidelines for fragile X syndrome

Clinician should test for *FMRI* mutation if the patient has any of the following:

- Mental Retardation* of unknown etiology
- Autism or Autism Spectrum Disorder* of unknown etiology (including pervasive developmental disorder-not otherwise specified or Asperger syndrome)
- Premature Ovarian Failure* of unknown etiology

Clinician should test for *FMRI* mutation if the patient has any of the following AND additional cognitive or physical features of FXS OR family history of FXS or FXTAS:

- Learning Disability*, especially Nonverbal Learning Disabilities or math disability
- Behavioral issues*, including poor eye contact, anxiety, selective mutism, attention problems, hyperactivity
- Seizures*

TABLE 4. Testing guidelines for fragile X-associated tremor/ataxia syndrome^a

Clinician should test for *FMRI* mutation if the patient has any of the following:

- Onset of cerebellar ataxia of unknown cause in an individual over 50 yr
- Onset of action tremor of unknown cause in individual over 50 yr with parkinsonism or cognitive decline
- Prior diagnosis of multiple system atrophy, cerebellar subtype MCP sign on T2/FLAIR images of MRI in a patient with signs consistent with FXTAS^b
- Positive family history of *FMRI* mutation in an individual who could be a carrier based on position in pedigree if signs consistent with FXTAS are present^b
- Family or patient history of infertility/premature menopause in a patient with signs consistent with FXTAS^b

^aPresence of an MCP sign (increased T2 signal intensity in the middle cerebellar peduncles), family history of *FMRI* mutation and possible carrier status, and patient history of POF (premature ovarian failure), even without clinical signs of FXTAS would be appropriate criteria for *presymptomatic* screening for an *FMRI* mutation.

^bSigns consistent with classic FXTAS include action tremor, cerebellar gait ataxia, parkinsonism, and cognitive decline, especially executive function deficits. Additional features that are often associated with, or may be the presenting features of FXTAS, include peripheral neuropathy, autonomic dysfunction, dementia, a family history of ataxia, autism spectrum disorder or mental retardation, and a family or personal history of POF. Males are more commonly affected than females.

two years; onset of falls, six years; dependence on a walking aid, 15 years; and death, 21 years. Preliminary data on life expectancy were variable, ranging from five to 25 years. In the few months before death patients were bedridden, dysarthric, dysphagic, without bladder or bowel control, and had severe parkinsonism (rigidity, rest tremor, and bradykinesia).

TREATMENT AND MANAGEMENT OF INDIVIDUALS WITH FXTAS

There is no specific treatment for FXTAS that is targeted to the underlying pathogenic mechanism of excess *FMRI* mRNA; however, there are several approaches for supportive intervention and parameters for clinical monitoring which should be considered standard once an individual is identified as having FXTAS. These include:

- treatment for specific neurological and psychiatric symptoms;
- monitoring for progression and degeneration;
- Treatment of hypertension because hypertension adds additional risk for compromise of cerebral white matter if left untreated
- referral to psychiatry, gerontology, movement disorder specialist, speech therapy for evaluation and management of swallowing if necessary, occupational and/or physical therapy; and

- genetic counseling for the patient and family.

As yet there have been no therapeutic clinical trials conducted in FXTAS, likely due to the only recent recognition of the disorder and presentation of these patients to general neurologists and primary care physicians. A questionnaire-based study of 56 patients with FXTAS reported that 60% were not on medications for their neurological symptoms.⁹¹ Those individuals with definite or probable FXTAS were more likely to be on medications than those with possible FXTAS. The questionnaire study design⁹² may have underestimated reported effectiveness, because of small sample sizes, cognitive impairment, and lack of insight into some of the symptoms of the disease.

On the basis of the questionnaire study⁹¹ and our anecdotal experience, some interventions for symptomatic control in FXTAS seem reasonable. Tremor may improve with primidone, β -blockers, and benzodiazepines. Some patients report mild, usually transient, improvement in ataxia from amantadine, and in parkinsonism from carbidopa/levodopa. An anecdotal report noted that gabapentin appeared to be helpful for neuropathic pain in some patients with FXTAS.³⁴

Both the anxiety disorder and depressive disorders associated with FXTAS may benefit from conventional management with antidepressant medications, such as selective serotonin reuptake inhibitors or serotonin-norepinephrine reuptake inhibitors.^{34,91} Anxiety improved in 2 of 6 FXTAS patients on venlafaxine and 5 of 8 patients on benzodiazepines.⁹¹ Because of the progressive nature of FXTAS and its association with dementia, benzodiazepines (and their associated risks to cognitive function), and tricyclic antidepressants (which are anticholinergic and thus problematic in patients at risk for cognitive impairment) should be used with caution.⁹³⁻⁹⁵

Although the profile of cognitive deficits in FXTAS appears to be different from those classically seen in AD, and a hypocholinergic state in FXTAS has not been elucidated, the use of anti-dementia medications may at least temporarily increase cognitive function in FXTAS dementia. Clinical intervention with psychopharmacological agents, as is typically done for other subtypes of dementia, appears cautiously advisable in FXTAS dementia and may serve to stabilize cognitive function, at least in the short term.⁵⁰ Off-label use of anticholinesterase agents (e.g. donepezil, rivastigmine, galantamine) may supplement the putative functionally hypocholinergic condition reflected in poor cognitive function.^{34,50} In addition, off-label use of memantine to block a possible glutamate-associated excitotoxicity in FXTAS dementia may be considered. Prospective studies of neuro-

protective agents for FXTAS dementia are currently being designed. Intervention with antidepressants for the concurrent mood and anxiety disorders may have a salutary affect in enhancing cognition while treating anxiety and mood symptoms.⁵⁰ In the questionnaire study⁹¹ slowing of cognitive decline was reported by family members in 3 of 9 FXTAS patients on acetylcholinesterase inhibitors and in 2 of 6 on venlafaxine. For dementia cases with secondary psychotic symptoms (e.g. delusions and hallucinations), cautious use of atypical antipsychotic agents may also be helpful.⁵⁰

FAMILY HISTORY TO AID WITH DIAGNOSIS AND MANAGEMENT OF FXTAS FOR PRACTITIONERS

When a family member is identified as having FXTAS with confirmation by the presence of an *FMRI* premutation, it is imperative that the physician obtain a family history and refer the patient to a genetic counselor or geneticist so that genetic and psychosocial issues related to the diagnosis can be addressed. When obtaining a family history, the clinician must inquire about specific medical issues related to other family members as well as the patient.

In taking a detailed family history from a new patient with psychiatric and/or neurological symptoms in the spectrum of those that can be seen in FXTAS, the physician should ask targeted questions about:

- Children or grandchildren with mental retardation, autism, behavioral/learning disorders
- Daughters or female relatives with infertility, premature menopause
- Family members with ataxia or other neurological problems and psychiatric problems, including dementia, especially if in combination with a movement disorder. It is likely that a small fraction of cases previously diagnosed with multiple sclerosis with dementia and Parkinson's disease with dementia, in fact, had FXTAS, particularly when multiple family members are affected

The most important family history is likely to involve identifying individuals with possible symptoms of FXS in the family, as virtually all cases of FXTAS thus far described (outside of population screening studies) have been recognized because of a grandson or granddaughter, grandnephew or grandniece, or son with FXS. If present, the family history of FXTAS and of POF has, in most cases, been identified after the relationship with FXS was established. It is likely that this ascertainment pattern reflects the recent description of the syndrome, however, and limited knowledge of FXTAS outside of groups

working with FXS families. With increased awareness it is expected that individuals with FXTAS (and POF) will be identified independently of the diagnosis of FXS.

GENETIC COUNSELING ISSUES

Genetic counseling for fragile X disorders is particularly challenging because of the complex multigenerational inheritance, variable phenotype, and implications for families. All women with a premutation are at risk of having offspring with a full mutation and thus, FXS. All daughters of males with a premutation will be obligate carriers of the premutation. A detailed family pedigree can be obtained by a genetic counselor in order to provide genetic risk assessment for carrier status and risk of having affected or carrier offspring. When a male patient with FXTAS is identified, the patient's mother is then an obligate carrier. Therefore, offspring and relatives of the patient and his mother, including grandchildren, nieces, nephews, and cousins of the patient are at risk for FXS, or for carrying a premutation. Siblings of the patient are at risk to present with FXTAS, thus ataxia, psychiatric, and neurological problems need to be identified in family members.

When transmitted from father to daughter, the premutation may change size, but remains within the premutation range. Thus, all female offspring of the male patient with FXTAS will have inherited the *FMRI* premutation and are at increased risk to have ovarian dysfunction and fertility problems related to POF as well as offspring with FXS. A female family member may undergo (often expensive and invasive) fertility treatment while unaware that she may be a carrier of the premutation, and at risk of having an affected child.⁹⁶ In addition, daughters of patients with FXTAS may experience neuropsychiatric problems such as anxiety, depression, and obsessive-compulsive behaviors. The premutation is unstable and may expand to a full mutation or stay within the premutation size range when passed from a mother to her children, depending on the size of the maternal allele.¹⁰ Thus, all grandchildren through daughters of the male patient with FXTAS are at a 50% risk to inherit the *FMRI* pre- or full mutation and all children of the female patient with FXS or FXTAS are at a 50% risk to inherit the *FMRI* pre- or full mutation.

Because of the complex genetic nature of FXS and its related disorders, all newly diagnosed patients with FXTAS and their families should be referred for genetic services. To locate a genetic counselor in your area, if there is not one at a nearby medical center, contact the relevant national association of genetic counselors or clinical geneticists (National Society of Genetic Counselors

at www.NSGC.org in the USA). For information on FXTAS contact the National Fragile X Foundation (NFXF) at www.fragilex.org, or one of the international fragile X associations or foundations accessible through the NFXF website at <http://www.fragilex.org/html/international.htm>.

CONCLUSION

In summary, FXTAS may be one of the most common progressive neurological disorders associated with a single gene defect in males, but it is currently under-diagnosed because it has only recently been described. Furthermore, the clinical presentation in individual patients is often nonspecific and symptoms may be brushed aside as secondary simply to aging. We urge neurologists, psychiatrists, and other clinicians who see patients with the symptoms described here to order fragile X (*FMRI*) DNA testing to identify patients affected by the premutation. Although tremor and ataxia are the hallmarks of the condition, the phenotype is highly variable; and parkinsonism, executive defects, dementia, other psychiatric problems, neuropathy, and autonomic symptoms are often observed in association with FXTAS. FXTAS should be considered in the differential diagnosis of dementia with a movement disorder. MR imaging studies can assist with diagnosis, particularly when the MCP sign is present, but also when volume loss involving cortex, cerebellum, and other subcortical structures is noted. Pathological studies show that FXTAS is an inclusion disorder, likely related to an RNA toxicity mechanism precipitated by an increased level of *FMRI* mRNA, which includes the CGG expansion. Diagnosis of FXTAS, as with other diseases with limited treatment potential, is important to allow the patient to understand the source of his/her symptoms and, to avoid unnecessary testing. For FXTAS, however, diagnosis is also crucial because daughters and other family members at risk of having children with FXS may be identified. Of note, symptomatic treatment can be provided with medications currently available for some of the neurological signs and psychiatric symptoms associated with FXTAS. In this report, we have provided guidelines for the practitioner to assist with identifying appropriate patients for FXTAS testing, and recommendations for genetic counseling once a diagnosis of FXTAS is made.

Acknowledgments: The focus group that led to this report was supported by a collaborative agreement with the Centers for Disease Control and Prevention (Grant No. U10/CCU925123). Work reported here was also supported by NIH grants HD36071 (RJH), NS044299 (JG), HD02274, and NS43532 (PJH).

LEGENDS TO THE VIDEO

Segment 1. Patient 1 (*FMRI* CGG count 106) is a 68-year-old man with progressive tremor for 19 years, gait ataxia for 11 years, and cognitive deficits for 7 years. Video demonstrates his large amplitude action head and bilateral hand tremor (kinetic > postural), unsteady gait, difficulty with tandem, and tremulous handwriting and spiral drawing. He has slightly reduced facial expression and moderate upper extremity rigidity.

Segment 2. Patient 2 (CGG count 112) is 66-year-old and is a brother of patient 1. He has had bilateral hand tremor for 16 years and no ataxia. He has mild executive function deficits. Video demonstrates his head and prominent arm tremor (kinetic > postural > rest) and lack of ataxia and parkinsonism.

Segment 3. Patient 3 (CGG count 125) is a 77-year-old man with gait ataxia for 12 years, hand tremor for eight years, and executive function deficits for about 5 years. The video shows his upper extremity action tremor (kinetic > postural), inability to tandem and mild parkinsonism (diminished facial expression and lack of left arm swing). He leans to the right as he walks.

REFERENCES

- Hagerman RJ, Leehey M, Heinrichs W, et al. Intention tremor, parkinsonism, and generalized brain atrophy in male carriers of fragile X. *Neurology* 2001;57:127-130.
- Jacquemont S, Hagerman RJ, Leehey M, et al. Fragile X premutation tremor/ataxia syndrome: molecular, clinical, and neuroimaging correlates. *Am J Hum Genet* 2003;72:869-878.
- Brunberg JA, Jacquemont S, Hagerman RJ, et al. Fragile X premutation carriers: characteristic MR imaging findings in adult males with progressive cerebellar and cognitive dysfunction. *Am J Neuroradiol* 2002;23:1757-1766.
- Bacalman S, Farzin F, Bourgeois JA, et al. Psychiatric phenotype of the fragile X-associated tremor/ataxia syndrome (FXTAS) in males: newly described fronto-subcortical dementia. *J Clin Psychiatry* 2006;67:87-94.
- Jacquemont S, Hagerman RJ, Leehey MA, et al. Penetrance of the fragile X-associated tremor/ataxia syndrome in a premutation carrier population. *JAMA* 2004;291:460-469.
- Rousseau F, Rouillard P, Morel ML, Khandjian EW, Morgan K, Rousseau F. Prevalence of carriers of premutation-size alleles of the *FMRI* gene—and implications for the population genetics of the fragile X syndrome. *Am J Hum Genet* 1995;57:1006-1018.
- Dombrowski C, Levesque ML, Morel ML, Rouillard P, Morgan K, Rousseau F. Premutation and intermediate-size *FMR1* alleles in 10 572 males from the general population: loss of an AGG interruption is a late event in the generation of fragile X syndrome alleles. *Hum Mol Genet* 2002;11:371-378.
- Verkerk AJ, Pieretti M, Sutcliffe JS, et al. Identification of a gene (*FMR-1*) containing a CGG repeat coincident with a breakpoint cluster region exhibiting length variation in fragile X syndrome. *Cell* 1991;65:905-914.
- Maddalena A, Richards CS, McGinniss MJ, et al., and Quality Assurance Subcommittee of the Laboratory Practice Committee. Technical standards and guidelines for fragile X: the first of a series of disease-specific supplements to the standards and guidelines for clinical genetics laboratories of the American College of Medical Genetics. *Genet Med* 2001;3:200-205.
- Nolin SL, Brown WT, Glicksman A, et al. Expansion of the fragile X CGG repeat in females with premutation or intermediate alleles. *Am J Hum Genet* 2003;72:454-464.
- Pieretti M, Zhang FP, Fu YH, et al. Absence of expression of the *FMR-1* gene in fragile X syndrome. *Cell* 1991;66:817-822.
- Devys D, Lutz Y, Rouyer N, Bellocoq JP, Mandel JL. The *FMR-1* protein is cytoplasmic, most abundant in neurons and appears normal in carriers of a fragile X premutation. *Nat Genet* 1993;4:335-340.
- Bear MF, Huber KM, Warren ST. The mGluR theory of fragile X mental retardation. *Trends Neurosci* 2004;27:370-377.
- Beckel-Mitchener A, Greenough WT. Correlates across the structural, functional, and molecular phenotypes of fragile X syndrome. *Ment Retard Dev Disabil Res Rev* 2004;10:53-59.
- Tassone F, Hagerman RJ, Iklé DN, et al. *FMRP* expression as a potential prognostic indicator in fragile X syndrome. *Am J Med Genet* 1999;84:250-261.
- Crawford DC, Meadows IL, Newman JL, et al. Prevalence and phenotypic consequence of *FRAXA* and *FRAXE* alleles in a large, ethnically diverse, special education-needs population. *Am J Hum Genet* 1999;64:495-507.
- Hagerman RJ, Hagerman PJ. *Fragile X Syndrome: diagnosis, treatment, and research*, 3rd ed. Baltimore: The Johns Hopkins University Press; 2002.
- Berry-Kravis E. Epilepsy in fragile X syndrome. *Dev Med Child Neurol* 2002;44:724-728.
- Riddle JE, Cheema A, Sobesky WE, et al. Phenotypic involvement in females with the *FMR1* gene mutation. *Am J Ment Retard* 1998;102:590-601.
- Loesch DZ, Hay DA, Mulley J. Transmitting males and carrier females in fragile X—revisited. *Am J Med Genet* 1994;51:392-399.
- Sobesky WE, Taylor AK, Pennington BF, et al. Molecular-clinical correlations in females with fragile X. *Am J Med Genet* 1996;64:340-345.
- Franke P, Leboyer M, Gansicke M, et al. Genotype-phenotype relationship in female carriers of the premutation and full mutation of *FMR-1*. *Psychiatry Res* 1998;80:113-127.
- Hessl D, Tassone F, Loesch DZ, et al. Abnormal elevation of *FMR1* mRNA is associated with psychological symptoms in individuals with the fragile X premutation. *Am J Med Genet B Neuropsychiatr Genet* 2005;139:115-121.
- Cornish KM, Kogan C, Turk J, et al. The emerging fragile X premutation phenotype: evidence from the domain of social cognition. *Brain Cogn* 2005;57:53-60.
- Farzin F, Perry H, Hessl D, et al. Autism spectrum disorders and attention deficit/hyperactivity disorder in boys with the fragile X premutation. *J Dev Behav Pediatr* 2006;27(2, Suppl 2):S137-S144.
- Goodlin-Jones B, Tassone F, Gane LW, Hagerman RJ. Autistic spectrum disorder and the fragile X premutation. *J Dev Behav Pediatr* 2004;25:392-398.
- Tassone F, Hagerman RJ, Taylor AK, et al. Clinical involvement and protein expression in individuals with the *FMR1* premutation. *Am J Med Genet* 2000;91:144-152.
- Aziz M, Stathopulu E, Callias M, et al. Clinical features of boys with fragile X premutations and intermediate alleles. *Am J Med Genet B Neuropsychiatr Genet* 2003;121:119-127.
- Sullivan AK, Marcus M, Epstein MP, et al. Association of *FMR1* repeat size with ovarian dysfunction. *Hum Reprod* 2005;20:402-412.
- Hundscheid RD, Braat DD, Kiemeneij LA, Smits A, Thomas CM. Increased serum FSH in female fragile X premutation carriers with either regular menstrual cycles or on oral contraceptives. *Hum Reprod* 2001;16:457-462.
- Tassone F, Greco C, Berman RF, et al. Clinical and molecular correlations in FXTAS. Presented at the 55th Annual Meeting of the American Society of Human Genetics, New Orleans, LA, October 25–29, 2005.

32. Hagerman RJ, Greco C, Chudley A, et al. Neuropathology and neurodegenerative features in some older male premutation carriers of fragile X syndrome. *Am J Hum Genet* 2001;8 (Suppl 69):177.
33. Berry-Kravis E, Lewin F, Wu J, et al. Tremor and ataxia in fragile X premutation carriers: blinded videotape study. *Ann Neurol* 2003; 53:616-623.
34. Jacquemont S, Farzin F, Hall D, et al. Aging in individuals with the FMR1 mutation. *Am J Ment Retard* 2004;109:154-164.
35. Leehey MA, Hagerman RJ, Landau WM, Grigsby J, Tassone F, Hagerman PJ. Tremor/Ataxia syndrome in fragile X carrier males. *Mov Disord* 2002;17:744-745.
36. Leehey MA, Berry-Kravis E, Min SJ, et al. Progression of tremor and ataxia in male carriers of the FMR1 premutation. *Mov Disord* 2007;22:203-206.
37. Loesch DZ, Churchyard A, Brotchie P, Marot M, Tassone F. Evidence for, and a spectrum of, neurological involvement in carriers of the fragile X pre-mutation: FXTAS and beyond. *Clin Genet* 2005;67:412-417.
38. Tassone F, Adams J, Berry-Kravis EM, et al. CGG correlates with age of onset of motor signs of the fragile X-associated tremor/ataxia syndrome (FXTAS). *Am J Med Genet* (in press).
39. Peters N, Kamm C, Asmus F, et al. Intrafamilial variability in fragile X-associated tremor/ataxia syndrome. *Mov Disord* 2006; 21:98-102.
40. Pugliese P, Annesi G, Cutuli N, et al. The fragile X premutation presenting as postprandial hypotension. *Neurology* 2004;63:2188-2189.
41. Berry-Kravis E, Goetz CG, Leehey MA, et al. Neuropathic features in fragile X premutation carriers. *Am J Med Genet* 2007;143:19-26.
42. Burk K, Globas C, Bosch S. Cognitive deficits in spinocerebellar ataxia type 1, 2, and 3. *J Neurol* 2003;250:207-211.
43. Bozeat S, Gregory C, Ralph M, Hodges J. Which neuropsychiatric and behavioural features distinguish frontal and temporal variants of frontotemporal dementia from Alzheimer's disease? *J Neurol Neurosurg Psychiatry* 2000;69:178-186.
44. Bak T, Crawford L, Hearn V, Mathuranath P, Hodges J. Subcortical dementia revisited: similarities and differences in cognitive function between progressive supranuclear palsy (PSP), corticobasal degeneration (CBD) and multiple system atrophy (MSA). *Neurocase* 2005;11:268-273.
45. Grigsby J, Brega AG, Leehey MA, et al. Impairment of executive cognitive functioning in males with fragile X-associated tremor/ataxia syndrome. *Mov Disord* 2007;22:645-650.
46. Grigsby J, Leehey MA, Jacquemont S, et al. Cognitive impairment in a 65-year-old male with the fragile X-associated tremor-ataxia syndrome (FXTAS). *Cogn Behav Neurol* 2006;19:165-171.
47. Grigsby J, Brega AG, Jacquemont S, et al. Impairment in the cognitive functioning of men with fragile X-associated tremor/ataxia syndrome (FXTAS). *J Neurol Sci* 2006;248:227-233.
48. Loesch DZ, Bui MQ, Grigsby J, et al. Effect of the fragile X status categories and the FMRP levels on executive functioning in fragile X males and females. *Neuropsychology* 2003;17:646-657.
49. Moore CJ, Daly EM, Schmitz N, et al. A neuropsychological investigation of male premutation carriers of fragile X syndrome. *Neuropsychologia* 2004;42:1934-1947.
50. Bourgeois JA, Farzin F, Brunberg JA, et al. Dementia with mood symptoms in a fragile X premutation carrier with the fragile X-associated tremor/ataxia syndrome: clinical intervention with donepezil and venlafaxine. *J Neuropsychiatry Clin Neurosci* 2006; 18:171-177.
51. Bourgeois J, Cogswell J, Hessel D, et al. Cognitive, anxiety, and mood disorders in the fragile X-associated tremor/ataxia syndrome (FXTAS). Submitted.
52. Berry-Kravis E, Potanos K, Weinberg D, Zhou L, Goetz CG. Fragile X-associated tremor/ataxia syndrome in sisters related to X-inactivation. *Ann Neurol* 2005;57:144-147.
53. Hagerman RJ, Leavitt BR, Farzin F, et al. Fragile-X-associated tremor/ataxia syndrome (FXTAS) in females with the *FMR1* premutation. *Am J Hum Genet* 2004;74:1051-1056.
54. Zuhlke C, Budnik A, Gehlken U, et al. FMR1 premutation as a rare cause of late onset ataxia—evidence for FXTAS in female carriers. *J Neurol* 2004;251:1418-1419.
55. Jacquemont S, Orrico A, Galli L, et al. Spastic paraparesis, cerebellar ataxia, and intention tremor: a severe variant of FXTAS? *J Med Genet* 2005;42:e14.
56. Storey E, Billimoria P. Increased T2 signal in the middle cerebellar peduncles on MRI is not specific for fragile X premutation syndrome. *J Clin Neurosci* 2005;12:42-43.
57. Okamoto K, Tokiguchi S, Furusawa T, et al. MR features of diseases involving bilateral middle cerebellar peduncles. *AJNR Am J Neuroradiol* 2003;24:1946-1954.
58. Cohen S, Masyn K, Adams J, et al. Molecular and imaging correlates of the fragile X-associated tremor/ataxia syndrome. *Neurology* 2006;67:1426-1431.
59. Moore CJ, Daly EM, Tassone F, et al. The effect of pre-mutation of X chromosome CGG trinucleotide repeats on brain anatomy. *Brain* 2004;127:2672-2681.
60. Loesch DZ, Litewka L, Brotchie P, Huggins RM, Tassone F, Cook M. Magnetic resonance imaging study in older fragile X premutation male carriers. *Ann Neurol* 2005;58:326-330.
61. Greco C, Hagerman RJ, Tassone F, et al. Neuronal intranuclear inclusions in a new cerebellar tremor/ataxia syndrome among fragile X carriers. *Brain* 2002;125:1760-1771.
62. Greco CM, Berman RF, Martin RM, et al. Neuropathology of fragile X-associated tremor/ataxia syndrome (FXTAS). *Brain* 2006;129 (Part 1):243-255.
63. Louis E, Moskowitz C, Friez M, Amaya M, Vonsattel JP. Parkinsonism, dysautonomia, and intranuclear inclusions in a fragile X carrier: a clinical-pathological study. *Mov Disord* 2006;21:420-425.
64. Arocena DG, Iwahashi CK, Won N, et al. Induction of inclusion formation and disruption of lamin A/C structure by premutation CGG-repeat RNA in human cultured neural cells. *Hum Mol Genet* 2005;14:3661-3671.
65. Iwahashi CK, Yasui DH, An H-J, et al. Protein composition of the intranuclear inclusions of FXTAS. *Brain* 2006;129:256-271.
66. Tassone F, Iwahashi C, Hagerman PJ. FMR1 RNA within the intranuclear inclusions of fragile X-associated tremor/ataxia syndrome (FXTAS). *RNA Biol* 2004;1:103-105.
67. Hagerman PJ, Hagerman RJ. The fragile-X premutation: a maturing perspective. *Am J Hum Genet* 2004;74:805-816.
68. Tassone F, Hagerman RJ, Taylor AK, Gane LW, Godfrey TE, Hagerman PJ. Elevated levels of *FMR1* mRNA in carrier males: a new mechanism of involvement in fragile X syndrome. *Am J Hum Genet* 2000;66:6-15.
69. Van Dam D, Errijgers V, Kooy RF, et al. Cognitive decline, neuromotor and behavioural disturbances in a mouse model for fragile-X-associated tremor/ataxia syndrome (FXTAS). *Behav Brain Res* 2005;162:233-239.
70. Jin P, Zarnescu DC, Zhang F, et al. RNA-mediated neurodegeneration caused by the fragile X premutation rCGG repeats in *Drosophila*. *Neuron* 2003;39:739-747.
71. Greco CM, Soontrapornchai K, Wiroganon J, Gould JE, Hagerman PJ, Hagerman RJ. Testicular and pituitary inclusion formation in fragile X-associated tremor/ataxia syndrome (FXTAS). *J Urol* (in press).
72. Milunsky JM, Maher TA. Fragile X carrier screening and spinocerebellar ataxia in older males. *Am J Med Genet* 2004;125:320.
73. Van Esch H, Dom R, Bex D, et al. Screening for FMR-1 premutations in 122 older Flemish males presenting with ataxia. *Eur J Hum Genet* 2005;13:121-123.
74. Biancalana V, Toft M, Le Ber I, et al. FMR1 premutations associated with fragile X-associated tremor/ataxia syndrome in multiple system atrophy. *Arch Neurol* 2005;62:962-966.

75. Garland EM, Vnencak-Jones CL, Biaggioni I, Davis TL, Montine TJ, Robertson D. Fragile X gene premutation in multiple system atrophy. *J Neurol Sci* 2004;227:115-118.
76. Macpherson J, Waghorn A, Hammans S, Jacobs P. Observation of an excess of fragile-X premutations in a population of males referred with spinocerebellar ataxia. *Hum Genet* 2003;112:619-620.
77. Deng H, Le W, Jankovic J. Premutation alleles associated with Parkinson disease and essential tremor. *JAMA* 2004;292:1685-1686.
78. Brussino A, Gellera C, Saluto A, et al. *FMR1* gene premutation is a frequent genetic cause of late-onset sporadic cerebellar ataxia. *Neurology* 2005;64:145-147.
79. Tan EK, Zhao Y, Puong KY, et al. Expanded *FMR1* alleles are rare in idiopathic Parkinson's disease. *Neurogenetics* 2005;6:51-52.
80. Tan EK, Zhao Y, Puong KY, et al. Fragile X premutation alleles in SCA, ET, and parkinsonism in an Asian cohort. *Neurology* 2004;63:362-363.
81. Toft M, Aasly J, Bisceglia G, et al. Parkinsonism, FXTAS, and *FMR1* premutations. *Mov Disord* 2005;20:230-233.
82. Jacquemont S, Leehey MA, Hagerman RJ, Beckett LA, Hagerman PJ. Size bias of fragile X premutation alleles in late-onset movement disorders. *J Med Genet* 2006;43:804-809.
83. Gilman S, Low PA, Quinn N, et al. Consensus statement on the diagnosis of multiple system atrophy. *J Neurol Sci* 1999;163:94-98.
84. Seixas AI, Maurer MH, Lin M, et al. FXTAS, SCA10, and SCA17 in American patients with movement disorders. *Am J Med Genet A* 2005;136:87-89.
85. Cellini E, Forleo P, Ginestroni A, et al. Fragile X premutation with atypical symptoms at onset. *Arch Neurol* 2006;63:1135-1138.
86. Kamm C, Healy DG, Quinn NP, et al. The fragile X tremor ataxia syndrome in the differential diagnosis of multiple system atrophy: data from the EMSA Study Group. *Brain* 2005;128 (Part 8):1855-1860.
87. Garcia Arocena D, Louis ED, Tassone F, et al. Screen for expanded *FMR1* alleles in patients with essential tremor. *Mov Disord* 2004;19:930-933.
88. Hedrich K, Pramstaller PP, Stubke K, et al. Premutations in the *FMR1* gene as a modifying factor in Parkin-associated Parkinson's disease? *Mov Disord* 2005;20:1060-1062.
89. Kamm C, Gasser T. The variable phenotype of FXTAS: a common cause of "idiopathic" disorders. *Neurology* 2005;65:190-191.
90. Hall DA, Berry-Kravis E, Jacquemont S, et al. Initial diagnoses given to persons with the fragile X associated tremor/ataxia syndrome (FXTAS). *Neurology* 2005;65:299-301.
91. Huang D, Yang Q, Yu C. Allele frequencies of four short tandem repeat loci in Chinese Han population. *J Forensic Sci* 2003;48:1433-1434.
92. Hall DA, Berry-Kravis E, Hagerman RJ, Hagerman PJ, Rice CD, Leehey MA. Symptomatic treatment in the fragile X-associated tremor/ataxia syndrome. *Mov Disord* 2006;21:1741-1744.
93. Hall DA, Hagerman RJ, Hagerman PJ, Jacquemont S, Leehey MA. Prevalence of *FMR1* repeat expansions in movement disorders: a systematic review. *Neuroepidemiology* 2006;26:151-155.
94. Oxman TE. Antidepressants and cognitive impairment in the elderly. *J Clin Psychiatry* 1996;57 (Suppl 5):38-44.
95. Hulse GK, Lautenschlager NT, Tait RJ, Almeida OP. Dementia associated with alcohol and other drug use. *Int Psychogeriatr* 2005;17 (Suppl 1):S109-S127.
96. Gray SL, Lai KV, Larson EB. Drug-induced cognition disorders in the elderly: incidence, prevention and management. *Drug Saf* 1999;21:101-122.
97. Corrigan EC, Raygada MJ, Vanderhoof VH, Nelson LM. A woman with spontaneous premature ovarian failure gives birth to a child with fragile X syndrome. *Fertil Steril* 2005;84:1508.